DETECTION OF GLUCOMA USING DECISION TREE

G.Loganayaki[1], Dr.T.Samraj Lawrence[2]
[1]PG Student, [2]Associate professor
[1,2]Department of CSE, Francis Xavier Engineering College, Tirunelveli.

ABSTRACT

Glaucoma is a neurodegenerative disorder of the optic nerve, which causes partial loss of vision. Large number of people suffers from eye diseases in rural and semi urban areas all over the world. Current diagnosis of retinal disease relies upon examining retinal fundus image using image processing. The key image processing techniques to detect eye diseases include image registration, image fusion, image segmentation, feature extraction, image enhancement, morphology, pattern matching, image classification, analysis and statistical measurements. This paper proposes image processing technique for the early detection of glaucoma. Glaucoma is one of the major causes which cause blindness but it was hard to diagnose it in early stages. In this paper glaucoma is classified by extracting two features using retinal fundus images. (i) Cup to Disc Ratio (CDR). (ii) Ratio of Neuro Retinal Rim in inferior, superior, temporal and nasal quadrants i.e. (ISNT quadrants) to check whether it obeys or violates the ISNT rule. The novel technique is implemented on 50 retinal images and an accuracy of 94% is achieved taking an average computational time of 1.42 seconds.

Keywords— Retinal Fundus; Optic Disc; Optic Cup; CDR; NRR

I. INTRODUCTION

Lots of people in rural and semi-urban areas suffer from eye diseases such as Diabetic Retinopathy, Glaucoma, Age based Macular Degradation etc. Glaucoma is a pathological condition of optic nerve damage and is second leading cause of vision loss. It is known as silent thief of sight. It comes along with an ongoing destruction of optic nerve head (ONH) caused by an increase in intraocular pressure within eye. The optic nerve carries image information to brain. Due to damage to large number of nerve fibres, a blind spot is created leading to loss of vision. One of the indicators of glaucomatous eye is change in appearance of optic disk. Optic disk is elliptical in shape having bright orange-pink color with a pale centre. Due to degeneration of nerve fibre orange pink color disappears and become pale. i.e enlargement of depression called cup and thinning of neuro retinal rim. The pale centre called cup is devoid of neuro retinal tissue. For normal eye, cup-to-disc ratio is 0.3 to 0.5. For glaucomatous eye, ratio becomes 0.8.

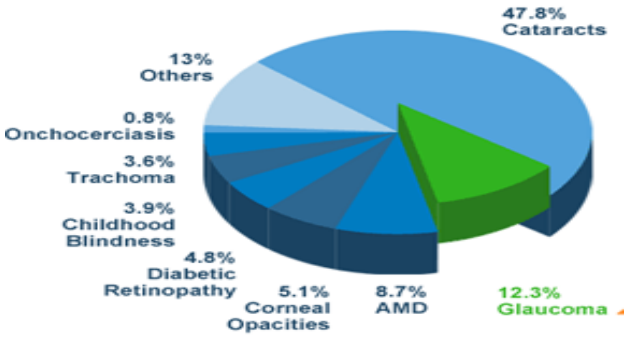

Glaucoma often causes permanent blindness slowly without symptoms and warnings. It is a primary cause of vision loss worldwide. It is the group of the disease that contaminates the optic nerve and the optic nerve cells

which results in loss of vision. In healthy eyes, there is normal balance between the fluids, one that is produced in the eye, and the second that leaves the eye through eye's drainage system. This balance of fluids keeps Inter Ocular Pressure (IOP) within the eye constant but in glaucoma, the balance of fluids produced within the eye is not maintained properly which in turn causes an increase in IOP, resulting in the damage of optic nerve. Due to increase in IOP, the cup size begins to increase which consequently increases the Cup to Disc Ratio. As For normal disc the CDR is considered to be less than 0.5 but in case of glaucoma, it is greater than 0.5. As the cup size increases it also affects the Neuro retinal Rim (NRR). NRR is the region located between the edge of the disc and the physiological cup. In the presence of glaucoma, area ratio covered by NRR in superior and inferior region becomes thin as compared to area covered by NRR in nasal and temporal region. The digital fundus image of a normal eye and glaucoma tic disc and inferior, superior, nasal and temporal (ISNT quadrants) are illustrated in Fig. 1.

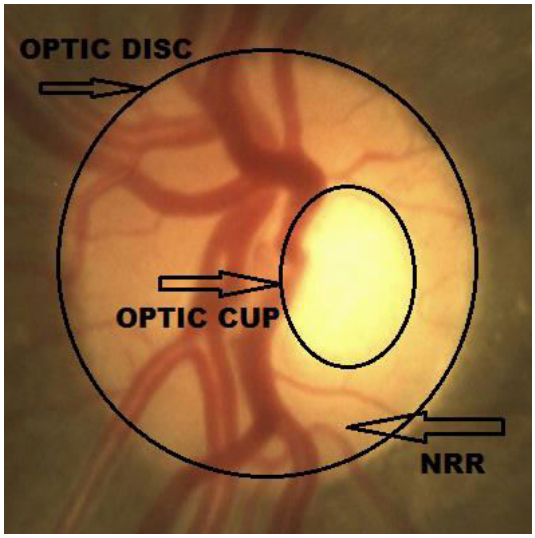

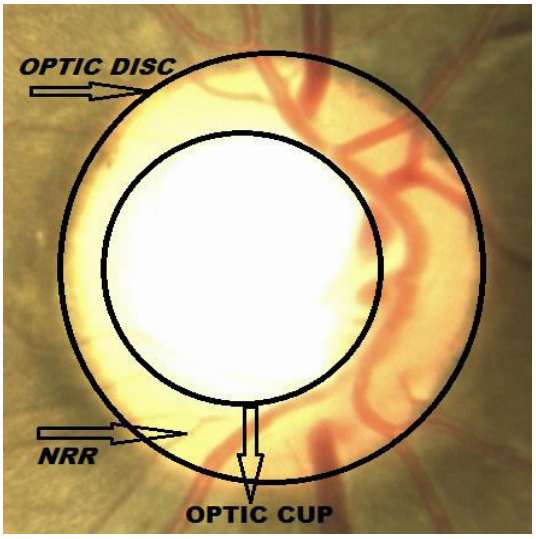

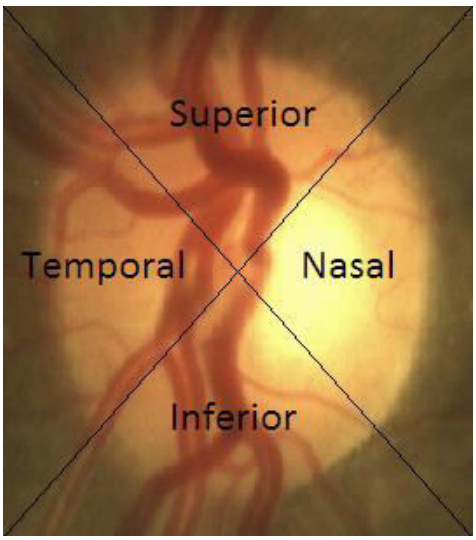

Fig. 1: L to R: Normal Disc (CDR<0.5), Glaucoma tic Disc (CDR>0.5), ISNT Quadrants.

II. RELATED WORK

An automated detection system using nonlinear higher order statistics (HOS) based method is used to capture the detailed information present in the fundus image efficiently. The center slice of bispectrum and bicepstrum are applied on fundus images [1]. The authours proposed

a method to automatically segment the Optic Disc and Cup from a low contrast retinal fundus image for further diagnosis by the doctor. The proposed method consists of three main steps including pre-processing, region localization and Optic Disc and Cup extraction [2]. A deep learning architecture, named M-Net, which solves the OD and OC segmentation jointly in a one-stage multilabel system. The proposed M-Net mainly consists of multi-scale input layer, U-shape convolutional network, side-output layer, and multi-label loss function. The multi-scale input layer constructs an image pyramid to achieve multiple level receptive field sizes. The U-shape convolutional network is employed as the main body network structure to learn the rich hierarchical representation, while the side-output layer acts as an early classifier that produces a companion local prediction map for different scale layers. Finally, a multi-label loss function is proposed to generate the final segmentation map [6]. The Krill Herd (KH) algorithm was implemented to obtain the optimal clusters. The diagnosis of Glaucoma can be done through measurement of Cup to Disc Ratio (CDR), it is calculated after determining the optic disc and cup boundary. The normal cup to disc ratio ranges from 1.1 to 1.3. If the cup to disc ratio exceeds 1.3 then it indicates the abnormal condition that is the presence of glaucoma [7]. It presents a fully automatic regression based method which accurately segments optic cup and disc in retinal colour fundus image. First, we roughly segment optic disc using circular hough transform. The approximated optic disc was then used to compute the initial optic disc and cup shapes. It was a robust and efficient cascaded shape regression method which iteratively learns the final shape of the optic cup and disc from a given initial shape. Gradient boosted regression trees are employed to learn each regressor in the cascade [11].

III.SYSTEM FLOW DIAGRAM

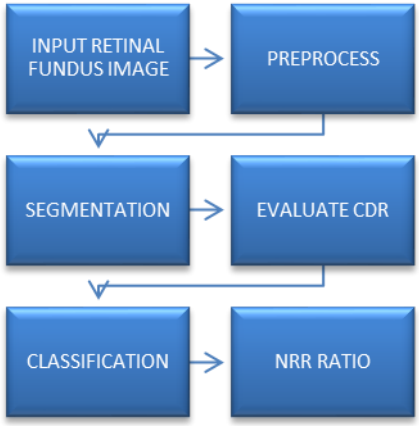

IV. PROPOSED METHODOLOGY

To identify glaucoma, two features are required to be extracted by Mean Threshold Morphological method in order to evaluate CDR and to find NRR ratio in ISNT quadrants. For CDR evaluation, optic disc and cup is required and to find NRR ratio in ISNT quadrants, NRR itself is required.

A. Image Preprocessing

In colour retinal images, Optic disc appears to be the brightest part having pink or light orange colour and is considered to be Region of Interest (ROI). The ROI from all images is crop down and is resized to

256×256. The original coloured fundus image was converted to HSV plane. After analysing a number of images, it was concluded that optic disc has a better contrast in V plane extract from HSV image shown in fig. 2.

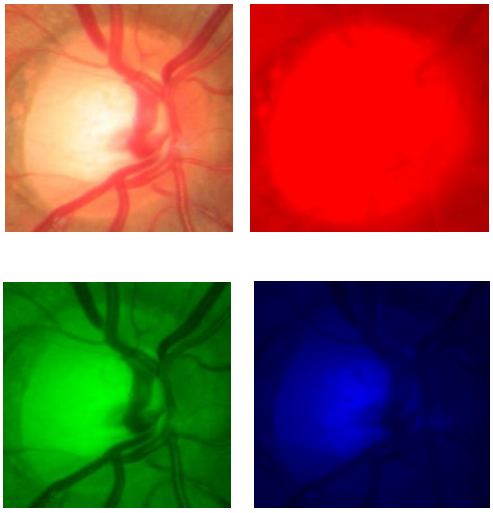

For extraction of optic cup, the green plane is extracted from original image which provides better contrast for optic cup.

B. Extraction of Optic Disc and Cup

To suspect glaucoma, evaluation of CDR is one of the key element, which is calculated by the extraction of optic disc and cup. The V plane from HSV image is extracted from the original retinal image shown in fig. 2. This is then converted to gray scale image. After calculating the mean value of the gray scale image; this value was set as threshold for converting it to binary image. The unwanted objects obtained in resultant binary image were labelled and removed by thresholding. This threshold helps in removing all the unwanted objects except the optic disc. In next step, as blood vessels were not removed in beginning so the resultant binary optic disc had gaps in it. To overcome this drawback the morphological operation were applied to the image. Image dilated by using the structuring element "DISK". This dilation results in filling all internal gaps but increasing the size of optic disc which will affect the CDR. after dilation the image is being eroded by same structuring element and size. Further the Gaussian filter is applied to the resultant image to smoothen the boundaries of the images shown in fig.3.





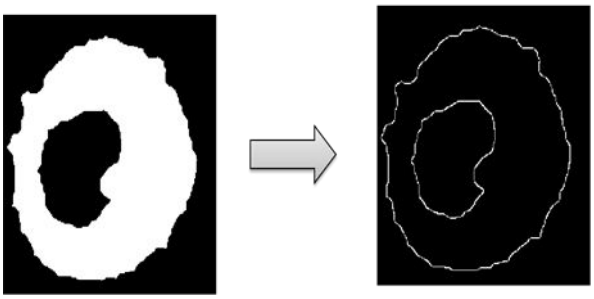

For the extraction of cup, green plane is converted to gray scale image; the cup has much brighter contrast as compared to other regions of fundus image. So the brightest pixels value is set as a threshold to get the binary image of optic cup. Threshold value for the extraction of cup varies because there is gradual transition in cup color by which boundary of cup is not much clear. The binary threshold value for DMED data ranges from 0.45 to 0.55, whereas the threshold value for images taken from FAU database library and MESSIDOR ranges between the 0.3 to 0.45. After extracting the binary optic cup shown in fig.3 (i), gaps caused by the presence of blood vessels are removed by dilation and then eroded, keeping the structuring element and its size same as used for binary optic disc. To smoothen the boundaries of optic cup, Gaussian filter is applied to the resultant binary image of the optic cup. The area is calculated by counting the number of white pixels after that, the area of cup is divided by the area of disc to calculate CDR. For edge dectection "Canny filter" is applied on resultant binary images of both optic disc and cup. Results of mean threshold and morphological method and edged of disc and cups are illustrated in fig. 3.

C. Extraction of Neuro retinal Rim

Extraction of NRR is another feature used for the detection of glaucoma. If the ratio of area covered by the nasal plus temporal side is greater than the ratio of area covered by the superior plus inferior quadrant, it shows indication toward Glaucoma .The optic disc and optic cup is extracted separately shown in fig 3, it makes much easier to extract NRR by just applying AND operation on both resultant binary images of disc and cup. Extracted NRR is shown in fig. 4 (b). A mask image having size of (256×256) is applied on extracted NRR image to measure the ratio of area covered by NRR in the ISNT quadrants. For evaluating the ratio in ISNT quadrants separately, mask is rotated 900 each time. Fig. 4 shows the mask, its rotated version and area covered by NRR in ISNT Quadrants. The area covered by white pixels is counted for the evaluating the ISNT Ratio.

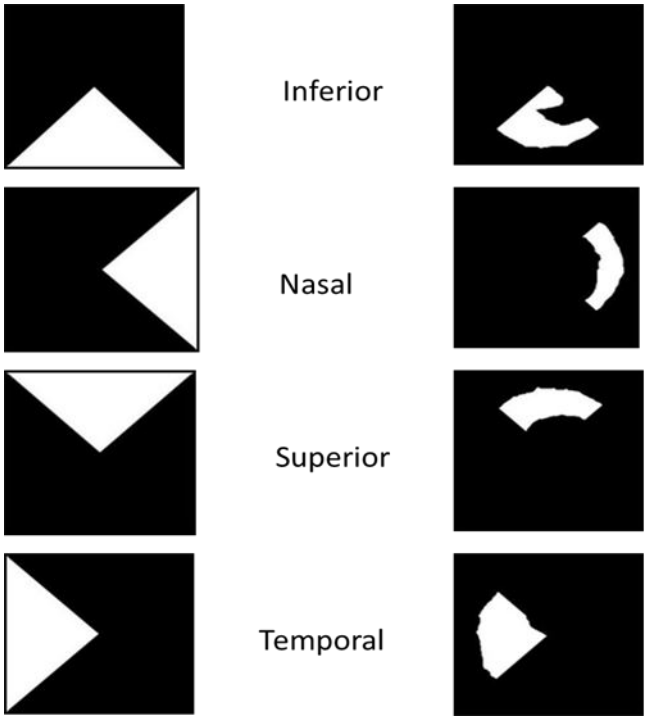

D. Classification

Classification has been done on bases of two features i.e. CDR and NRR ratio in ISNT quadrants. Disc with presence of glaucoma has CDR greater than 0.5 and it violates the ISNT rule whereas normal disc obeys ISNT rule and has CD ratio less than 0.5. If there is a tie between both features, disc is considered to be suspected. Based on the Area occupied by the segmented disk and the cup, CDR is computed. The optic disk and optic cup segmented image is given as the input. The CDR ratio is obtained at the output.

CDR=Area of cup/Area of Disc

ISNT Rule: Area covered by NRR in superior and inferior region becomes thin as compared to area covered by NRR in nasal and temporal region

V. RETINAL DATABASE COLLECTION

To develop the algorithm for automatic detection of glaucoma, the first essential step was to obtain the effective database and for that purpose 400 retinal images were collected in total with an image size of 700 X 605 with TIFF format. Stare (around 400 images are available). http://cecas.clemson.edu/~ahoover/stare/

Glucoma Normal Images

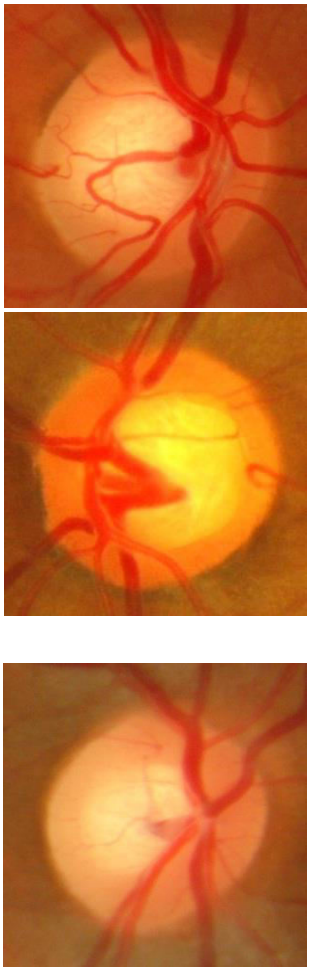

Glucoma Images

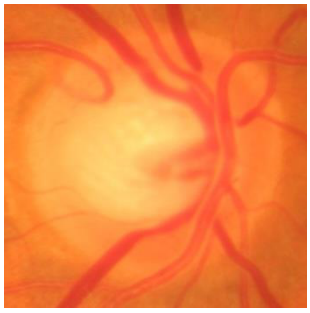

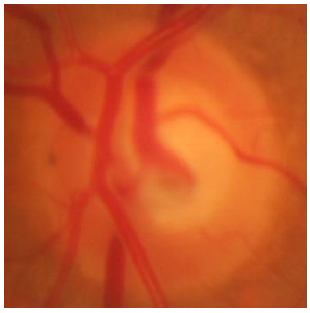

V.RESULTS

Towards the finalization of the exploration work, acquire the optimum precision of 97% for the location of Glaucoma Disease. By watching the components of the fundus Image by the strategies for CDR relying on the yield of the classifier, we will be able to distinguish Glaucoma. Subsequently, early detection of this sickness will assist us to take deterrent evaluation and estimation to predominate the infection in its initial course.

Table 5.1: Comparison of existing segmentation accuracy and Mean thresold accuracy

Method	Abnormal	Normal
Existing Gray Scale Threshold	86.6	80.9
Mean Threshold	93.3	95.23

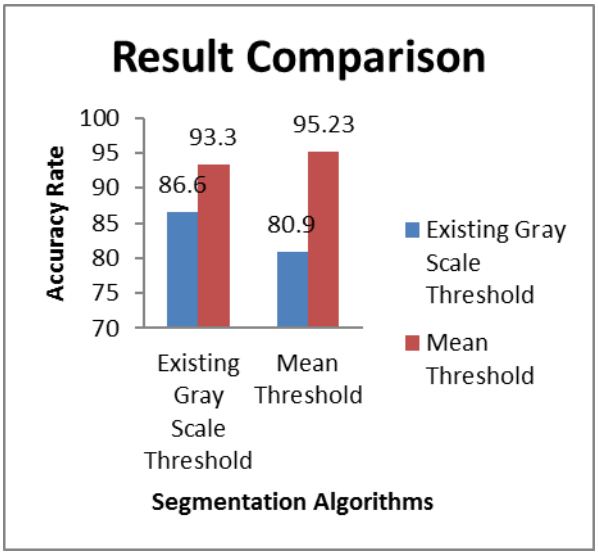

Figur 5.1 Comparison chart of segmentation algorithm accuracy

The above table shows an existing thresold algorithm only predict 86.6 percentage of abnormal glaucoma and 80.9 percentage of normal retinal fundus images. the comparison chart depicts the accuracy of the segmentation algorithms.

VI. CONCLUSION

In this paper, we designed and implemented an algorithm to identify glaucoma. The novel method uses Morphological techniques to extract two major features for detection of Glaucoma i.e. Cup to Disc Ratio, Area ratio of NRR in ISNT quadrants. The developed methods are tested on three different databases i.e., DMESSIDOR. The proposed method achieves an average accuracy of 94% having an average computational cost of 1.42 seconds.

REFERENCES

1. Rahul sharma, Pradip Sircar, R.B. Pachori, V. Bhandary and U. Rajendra Acharya, "Automated Glaucoma Detection using Center Slice of Higher Order Statistics", -(2018).

2. Chananchida Jaikla and Suwanna Rasmequan, "Segmentation of Optic Disc and Cup in Fundus Images using Maximally Stable Extremal Regions", Knowledge and Smart Technology Laboratory, Faculty of Informatics, Burapha University, Chonburi, Thailand – 2018.

3. A. Agarwal, A. Issac, A. Singh and M. K. Dutta, "Automatic imaging method for optic disc segmentation using morphological techniques and active contour fitting," 2016 Ninth International Conference on Contemporary Computing (IC3), Noida, 2016.

4. H. A. Nugroho, Ilcham, A. Jalil and I. Ardiyanto, "Segmentation of optic disc on retinal fundus images using morphological reconstruction enhancement and active contour," 2016 2nd International Conference on Science in Information Technology (ICSITech), Balikpapan, 2016.

5. S. Sedai, P. K. Roy, D. Mahapatra and R. Garnavi, "Segmentation of optic disc and optic cup in retinal fundus images using shape regression," 2016 - 38th Annual International Conference of the IEEE Engineering in Medicine and Biology Society (EMBC), Orlando.

6. "Joint Optic Disc and Cup Segmentation Based on Multi-label Deep Network and Polar Transformation", Huazhu Fu, Jun Cheng, Yanwu Xu, Damon Wing Kee Wong, Jiang Liu, and Xiaochun Cao, IEEE TRANSACTIONS ON MEDICAL IMAGING – 2018.

7. "Segmentation of Optic Disc and Optic Cup Using Krill Herd Algorithm for the Assessment of Glaucoma", Brindha T. Sambandam1, Dr. M.S. Josephine2 and Dr. V. Jeyabalaraja3, Chennai, India – 2017.

8. M.I. Ahmed, M.A. Amin, "High speed detection of optical disc in retinal fundus image", SIViP 9 (2015).

9. Pardha Saradhi Mittapalli, Giri Babu Kande - "Segmentation of optic disk and optic cup from digital fundus images for the assessment of glaucoma", Biomedical Signal Processing and Control - (2016).

10. K. Stapor, A. Switonski, R. Chractek, and G. Michelson, "Segmentation of fundus eye images using

methods of mathematical morphology for Glaucoma diagnosis", Inter. Conf. ICCS, 2004.

11. Suman Sedai, Pallab K. Roy, Dwarikanath Mahapatra and Rahil Garnavi "Segmentation of optic disc and optic cup in retinal fundus images using shape regression", (2016).

12. J. Ayub et al., "Glaucoma detection through optic disc and cup segmentation using K-mean clustering," 2016 International Conference on Computing, Electronic and Electrical Engineering (ICE Cube), Quetta, 2016.